

10. CENTRAL AND PERIPHERAL NERVOUS SYSTEM

10.1 Introduction

HHV-6 can infect and replicate in neuroglial cells, both *in vitro* as well as *in vivo*. The CNS is thought by some investigators to be one site of viral persistence. Both primary infections and non-primary infections (reactivation) by HHV-6 can cause serious CNS disease, preferentially by HHV-6A. Such diseases include meningitis and encephalitis in children with febrile seizures, acute necrotizing and hemorrhagic encephalitis, demyelinating disease in immune deficient patients. There is also increasing evidence of a certain pathogenetic role of HHV-6 in multiple sclerosis. Finally, HHV-6 neurotropism may as well play a significant role in the development of chronic fatigue syndrome (CFS, CFIDS). A summary of HHV-6 associated CNS diseases is presented in **Table 6**.

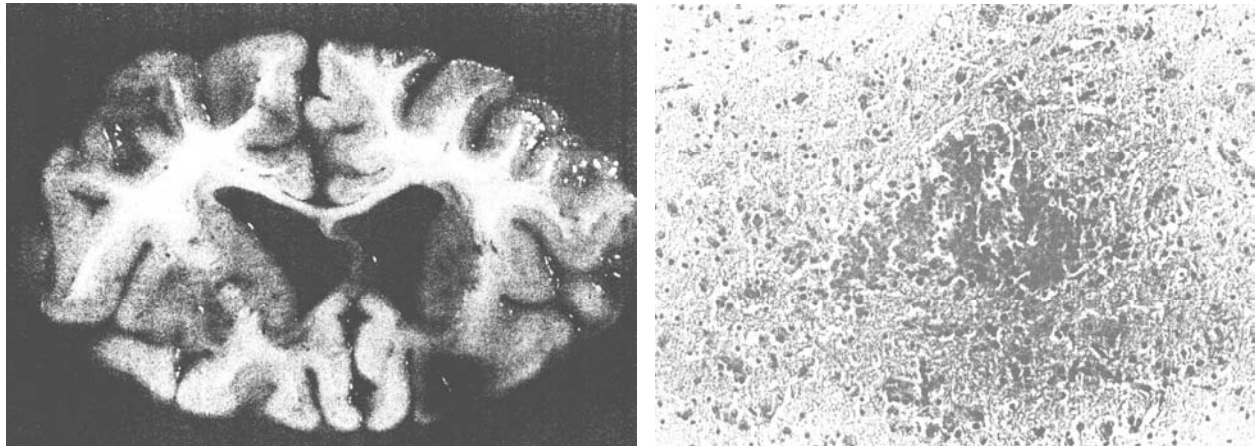
Pathologic Entity	Patient	Immune Status	HHV-6 Testing
Febrile seizures	children	nl	serology, virus isolation
meningitis, encephalitis, encephalomyelitis	children, adults	nl, immune deficient, post Tx	serology, PCR, virus isolation
hemorrhagic & necrotizing encephalitis	child	immune deficient	serology, IHC, ISH
demyelinating disease	children, adults	AIDSa.o. IDD	serology, PCR
progressive multifocal leukoencephalopathy (PML)	adult	ML, JCV coinfection	ISH, PCR
chronic fatigue syndrome	adults	?	serology, ACE, virus isolation
multiple sclerosis	adults	autoimmune	serology, PCR, virus isolation
peripheral neuropathy	adult	?	serology
"influenza" encephalopathy	children	primary influenza virus	CSF PCR

Table 6: Overview of HHV-6 associated CNS diseases. The last case in the table followed an influenza virus (IFV) infection, yet only HHV-6, not IFV were detected in the CSF. Abbreviations: nl = normal; post-Tx = post transplantation; PCR = polymerase chain reaction; IHC = immunohistochemistry; ISH = in situ hybridization; a.o. IDD = and other immune deficiency diseases; ML = malignant lymphoma; JVC = JC virus; ACE = antigen (p41)-capture ELISA; CSF - cerebrospinal fluid.

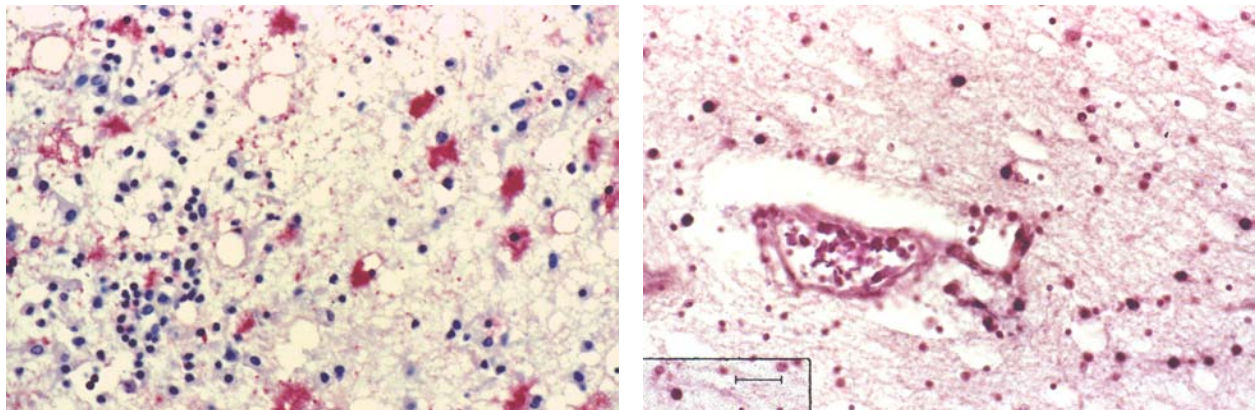
The exact role of HHV-6 in multiple sclerosis is still controversially discussed by some authors (Clark, 2004).

10.2 Figures

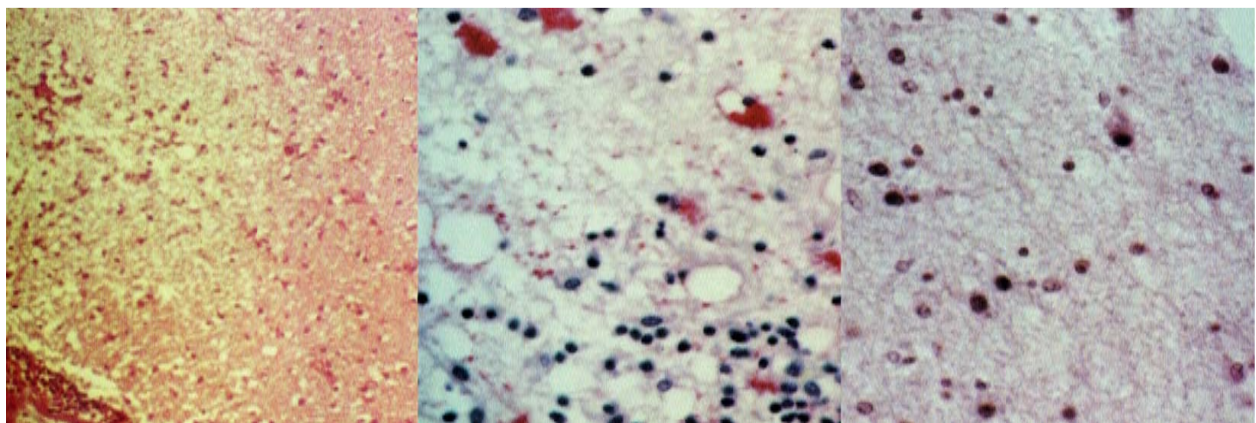
Acute necrotizing encephalitis in HHV-6 positive Griscelli's syndrome



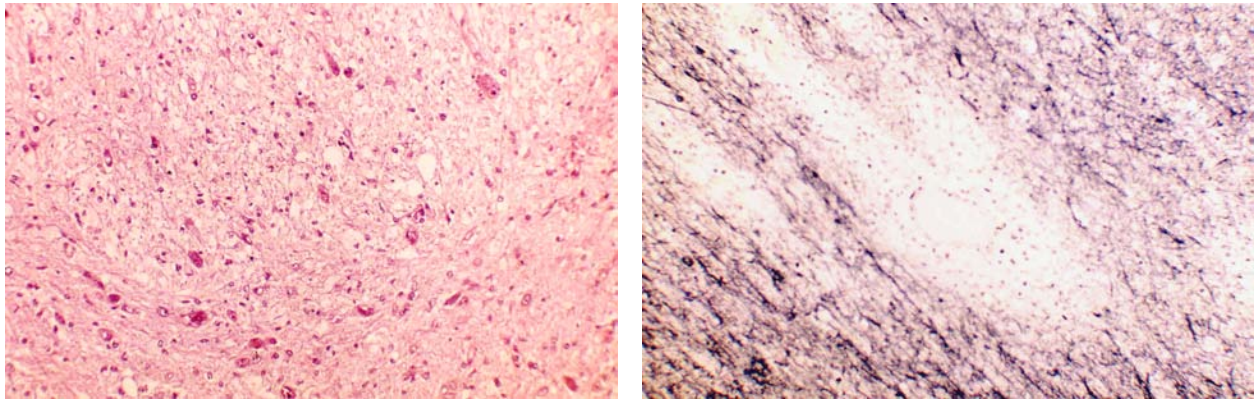
Gross & microscopic overview of hemorrhagic and necrotizing encephalitis in HHV-6A positive child



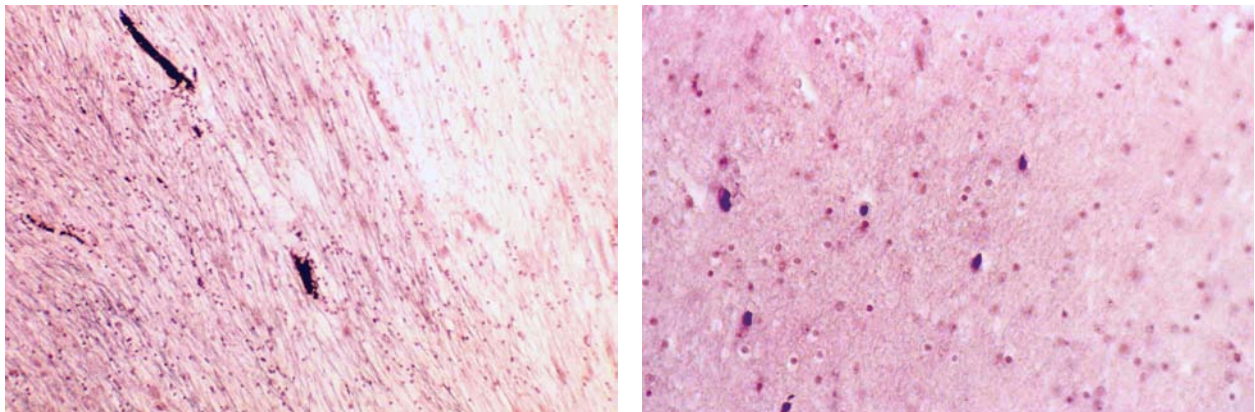
Immunocytochemistry for HHV-6 gp110/60 (left) and for in situ hybridization for HHV-6 DNA (top) as well as H&E stained microscopy showing focal demyelination (bottom left), immuno-



HHV-6 in multiple sclerosis



H&E (left) micrograph and of Klüver-Barrera stain (right) of focal demyelination in multiple sclerosis



Center of demyelination (left; residual myelin sheaths dark) and HHV-6A DNA in situ hybridization (right; black nuclei) indicating viral DNA at site of demyelination.

10.3 Further Reading

Hall CB, Caserta MT, Schnabel KC, Long C, Epstein LG, Insel RA, Dewhurst S. Persistence of human herpesvirus 6 according to site and variant: possible greater neurotropism of variant A. *Clin Infect Dis* 26: 132-137, 1998

Bonthius DJ, Karacay B. Meningitis and encephalitis in children. An update. *Neurol Clin* 10: 1013-1038, 2002

An SF, Groves M, Martinian L, Kuo LT, Scaravilli F. Detection of infectious agents in brain of patients with acute hemorrhagic leukoencephalitis. *J Neurovir* 8: 439-446, 2002

Soto-Hernandez JL. Human herpesvirus 6 encephalomyelitis. *Emerg Infect Dis* 10: 1700-1701, 2004

Wagner M, Muller-Berghaus J, Schroder R, Sollberg S, Luka J, Leyssens N, Schneider B, Krueger GRF. Human herpesvirus-6 (HHV-6) - associated necrotizing encephalitis in Griscelli's syndrome. *J Med Virol* 53: 306-312, 1997

Opsahl ML, Kennedy PG. Early and late HHV-6 gene transcripts in multiple sclerosis lesions and normal appearing white matter. *Brain* 128: 516-527, 2005

Sugaya N, Yoshikawa T, Muira M, Ishizuka T, Kawakami C, Asano Y. Influenza encephalopathy associated with infection with human herpesvirus 6 and/or human herpesvirus 7. *Clin Infect Dis* 34: 461-466, 2002

Daibata M, Hatakeyama N, Kamioka M, Nemoto Y, Hiroi M, Miyoshi I, Taguchi H. Detection of human herpesvirus 6 and JC virus in progressive multifocal leukoencephalopathy complicating follicular lymphoma. *Am J Hematol* 67: 200-205, 2001

Wagner M, Krueger GRF, Ablashi DV, Whitman JE. Chronic fatigue syndrome (CFS): A critical evaluation of testing for active human herpesvirus-6 (HHV-6) infection: Review of data from 107 cases. *J Chron Fatigue Syndr* 2: 3-16, 1996

Clark D. Human herpesvirus type 6 and multiple sclerosis. *Herpes* 11:112A-119A, 2004

Review article

Soldan SS, Goodman AD, Jacobson S. HHV-6 and the central nervous system. Chapter 16 in: Krueger GRF, Ablashi DV (eds.) *Human Herpesvirus-6*, 2nd. edition. Elsevier Science Publ, Amsterdam-London 2006